



Klinik  
am Steigerwald

Chinesische Medizin und  
biologische Heilverfahren

# Case-report: POST-COVID-SYNDROME

## Klinik am Steigerwald, Germany

Paul Schmincke

FA Allgemeinmedizin

Senior physician

Klinik am Steigerwald

[p.schmincke@tcmklinik.de](mailto:p.schmincke@tcmklinik.de)

0049 9382 949 115





# POST-COVID-SYNDROME

## Questions

- Do we face a lot of new qualities in Post-Covid-Syndrome and do we need new therapeutical approaches to this diagnosis?
- Is Post-Covid-Syndrome a new entity or just a variation of the known heterogenous group of **chronic Fatigue-Syndromes (CFS)**?



# Post-Covid-Symptoms: What is specific?

- Fatigue 58%
  - Headache 44%
  - Attention disorder 27%
  - Hairloss 25%
  - **Dyspnea 24%**
  - **Ageusia 23%, Anosmia 21%**
  - Cough 19%
  - Nausea 16%
  - Memory loss 16%
  - **Chest-discomfort 16%**
  - **Anxiety 13%**
  - **Palpitations 11%**
  - ...
- **Ageusia 23%, Anosmia 21%**
  - **Dyspnea 24%**
  - **Palpitations 11%**
  - **Chest-discomfort 16%**
  - **Nausea 16%**
  - **Anxiety 13%**



# Introduction

## Pathogenesis

Postinfectious CFS is mostly based on **chronic mucosal disorders**.

Chronic mucosal disorders are a result **inappropriate immune-response to acute infections** and therefore failed recovery.



# Introduction

## Phases of acute infection

- Activation, hyperperfusion, (wind-heat)
- Swelling, oedema, Leucocyte-migration, (dampness)
- Secretion
- Healing



# Introduction

## 3 types of CFS:

- I. (classic) Post-EBV type:  
with predominant lymphatic disorder, latent heat, dry (lung)
- II. Rheumatiforme disorder, cold (kidney)
- III. Metabolic disorder, dampness (stomach)
  
- IV. ? Post-Covid-Syndrome ?

# CFS type I: (classic) Post-EBV type, with lymphatic disorder. blood-heat (lung)

- Sore throat, mucosal destruction, ulcers, leucopenia
- Hepato-splenomegalia and lymph-nodes swollen
- Overactivity, restlessness **and fatigue**
- **T: red, defects or red spots, P: short, deplete, wiry**

**Strategy: cool heat, calm immune response**

## Decoction: Ning Jing Tang (Dr. Fritz Friedl)

Scutellaria baic. R 1g

Huangqin 1g

Forsythiae Fr 2g

Xuanshen 4g

Scrophularia R 4g

Lianqiao 2g

Lonicerae Fl 6g

Jinyinhua 6g



# CFS type II: Invaded cold disorder (kidney)

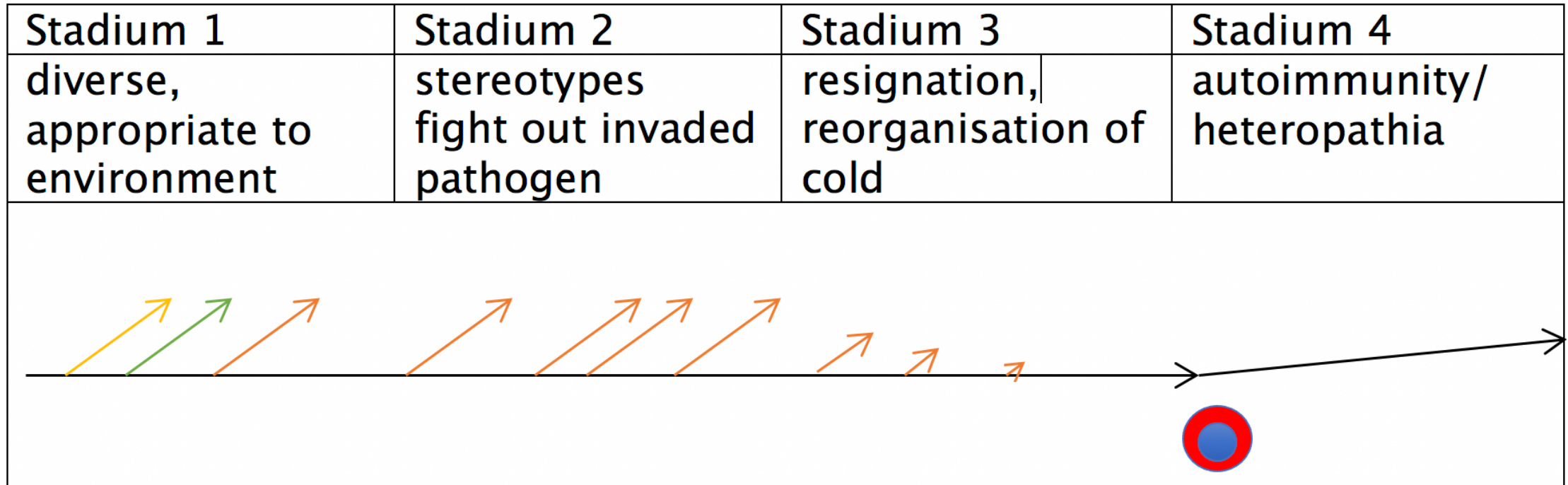
- Similar to rheumatic disorders
- Fibromyalgic pain
- **Often resulting from chronic recurrent sinu-bronchitis, cystitis**
- signs of resigned immune response in the case history
- T: blue, pale, dark spots      Pulse: deep, slow

**Decoction: PS-Strategies (Fritz Friedl)**





# History of cold invasion and reactive heat





# PS Strategies (Fritz Friedl)

- Phellodendri cx 1g                      Huangbo 1g
  - Saposhnikoviae R 3g                      Fangfeng 3g
- 
- Brings movement (warmth) in sunken cold nuclei, elevates the process from inner layers to surface, connects biao - li
  - CAVE: Contravection
  - Combine with any Strategy: moisten, dry, cool, heat, move, calm...



# CFS type III: Metabolic disorder, dampness (stomach)

- chronic swollen mucosa
- disorders of the middle jiao, nausea
- metabolic syndrome
- Pressure in the head, dizziness, allergy, asthma (swollen mucosa)

## **Main decoction: Scut-Kush** (Dr. Fritz Friedl) (many variations)

Scutellaria R baic. 2g

Artemisiae H. scop. 6g

Siegesbeckiae H. 3g

Dictamni Cx 2g

Rhei, Rh 2g

Huangqin 2g

Yinchenhao 6g

Xixiancao 3g

Baixianpi 2g

Dahuang 2g



# Therapeutical objective

Expel the pathogenic factor via the surface.

Reactivation of superficial acitivity, which means mucosal activity.



# W, 41 CEO and Author

COVID - 19 Infection March 2020

PCR 2x positive, Antibodys high positive

## **Symptoms during Infection:**

Dyspnoe NYHA III, palpitations, limb pain, headache, ageusia, cough, no fever, vaginal inflammation, sinusitis, otitis media, enteritis, fatigue.

No ITS.



# Present complaints (Nov. 2020)

- Severe Fatigue (working, walking, driving not possible)
- Sleep disorder, nightmares, weak concentration
- Muscle- and limb pain
- Sore throat
- weight gain 8kg
- Vegetative: Thirst, obstipation, normal menstruation, cold hands



# Findings

- Chalder Fatigue Scale 24 von 33 points. (severe CFS)
- CFS Schweregrade nach Bell: 30/100, 20/100
- SF36 20/100 Vitality 0/100
- Disorder autonomous nervous system: COMPASS 31: 64/100
- Tachycardia (POTS, postural orthostatic tachycardia syndrome)
- no humoral immune defect, no rheumatic disease
- CT Thorax ok
- **Antibody titer persistent high**



# Immune History

- 2004 Amoebiasis diarrhea
- 2005 Abrasio, uterine bleeding
- 2006-2008 **Recurrent cystitis**, headaches (antibiotics)
- 2014 Uterine myoma, OP
- 2014-2018 recurrent **sinusitis and bronchitis (antibiotics)**
- 2018 laryngitis and **recurrent cystitis**
- 2019 **laryngitis, cystitis, candida vaginitis, bronchitis**, pain limbs
- **03/2020 COVID-19 infection**, persistent sinusitis
- 04/2020 **Otitis media**, antibiotics
- Clostridium difficile **enteritis, diarrhea, vaginal candidiasis** and laryngitis
- **Persistent sinusitis: Lasercoagulation sinus nasalis 05/2020**





# 4-Mucosa Disorder

- **Sinu-bronchitis**
- **Enteritis**
- **Cystitis**
- **Vaginitis**



# Therapy 16/11/20

Findings, Anamnesis	therapeutical intention	Decotion	Result, interpretation
Pulse: shi, hua  T: Red, cover yellow. dark spots lower jiao	clean heat, expel humor, search for heteropathia (xie qi) recent infection: maybe reactivation possible	<b>Scutkush + Lonicera fl.</b>  Huangqin 2g Yinchenhao 6g Xixiancao 3g Baixianpi 2g Jinyinhua 6g	Emotional Depression, <b>Nose blocked</b> Stool still obstipated,  Problem: chronic sinusitis, post-OP too early reactivation with Scutellaria, Scut- Loni-Kush too depleting, not constructive



# Therapy 22/11/20

Findings, Anamnesis	therapeutical intention	Decotion	Result, interpretation
<p>Pulse: shi, hua</p> <p><b>T: more yellowish cover.</b> But dark spots lower jiao</p> <p><b>Obstipation,</b> Nose blocked, thirst ok now</p>	<p>-&gt; same strategy, but variation.</p> <p>Cool bowel mucosa, support bowel movement</p> <p>clean heat, expel humor</p>	<p><b>PS-MAL</b></p> <p>Huangbo 0,5g Fangfeng 1,5g Moudanpi 1g Niuxi 1g Digupi 1g</p> <p><b>Kushen-Tang</b></p> <p>Kushen 0,5g Yinchenhao 6g Xixiancao 3g Baixianpi 2g Dahuang 2g</p>	<p>Bowel movement better, smelly stool.</p> <p>Fatigue worse, Depression worse, Pain Hips (old Problem), Headache</p> <p>-&gt;Mobilisation ok, but too depleting: Compliance-Problem</p>



# Therapy 01/12/20

Findings, Anamnesis	therapeutical intention	Decotion	Result, interpretation
<p>Pulse: right side xu, left side hua</p> <p>T: yellowish cover, <b>big dark spots lower jiao</b></p> <p>VA: no more Obstipation. <b>Pain in the hips (reactivation)</b></p>	<p>2<sup>nd</sup> step strategy:</p> <p>careful moving qi in the interior, expel humor</p> <p><b>tackle “cold nucleus”</b></p>	<p><b>Phellokush</b></p> <p>Phellodendri 1 Saposhnikov. 3 Artemis. scop. 6 Siegesbeckia 3 Dictamni 2</p> <p><b>Huangbo 1g Fangfeng 3g Yinchenhao 6g Xixiancao 3g Baixianpi 2g</b></p>	<p>More Tremor, dizziness, but hands/feet warm, sleep well. better condition, 2km walking, bowel movement good.</p> <p><b>sore throat, vaginal inflammation (red, painful, not very itchy, no discharge)</b> <b>= Reactivation, heat comes up, but not aimed at nasal mucosa.</b></p>



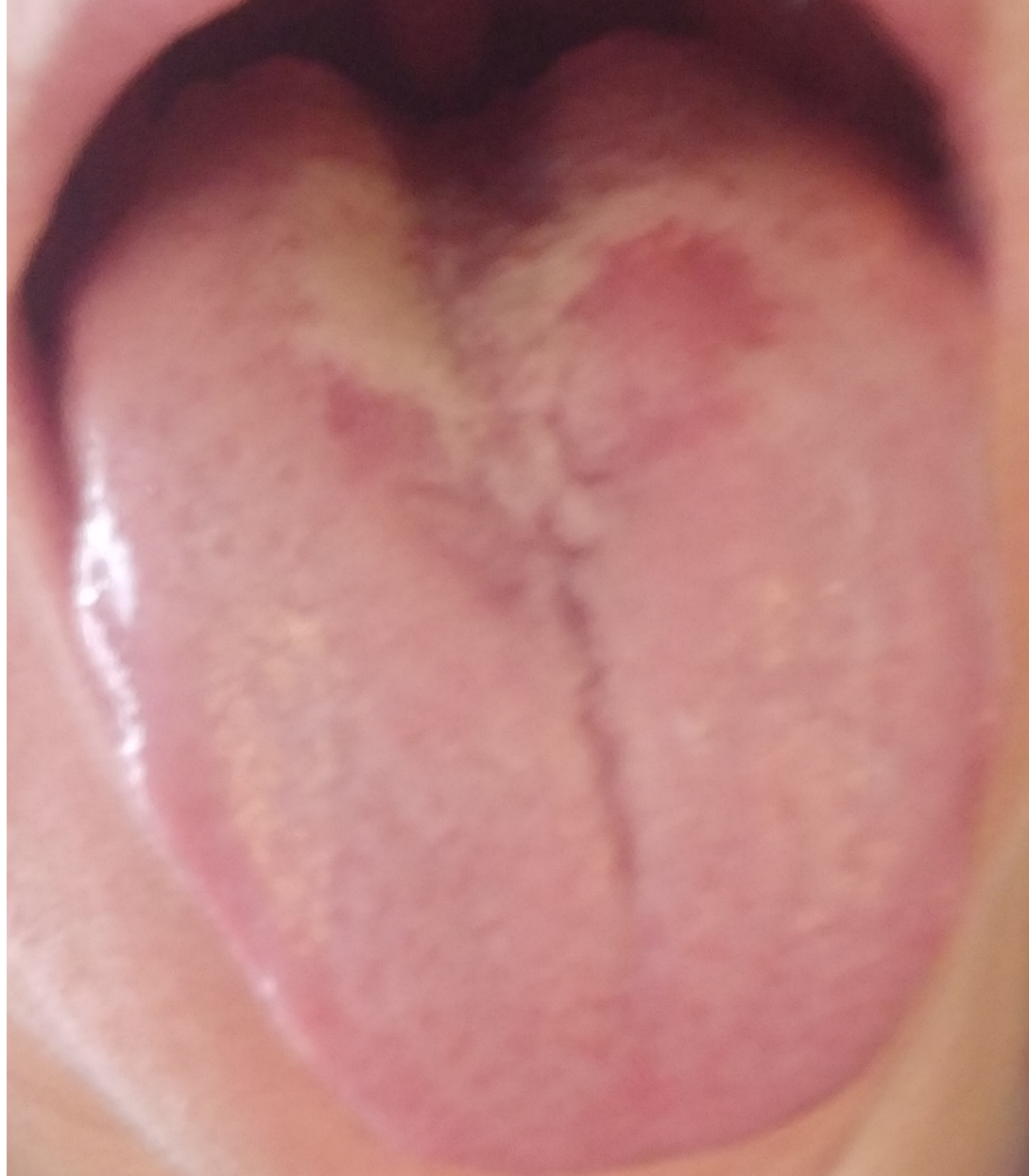# Therapy 14/12/20

Findings, Anamnesis	Therapeutical intention	Decotion	Result, interpretation
<p>T: Red, red tip, red spots, yellowish cover.</p> <p>No more pain</p> <p><b>sore throat + destructiv mucosal activity. (Part of Covid)</b> <b>= heat comes out</b></p>	<p>3<sup>rd</sup> step: cool heat</p>	<p><b>Ning Jing Tang</b></p> <p>Scutellaria R. 1 Scrophularia 4 Forsythia Fr 2 Lonicera Fl. 6</p> <p><b>Huangqin 1g</b> <b>Xuanshen 4g</b> <b>Lianqiao 2g</b> <b>Jinyinhua 6g</b></p>	<p>Vaginal inflammation gone.</p> <p><b>Develops otitis media, blocked Valsalva, little mucus out of nose.</b></p> <p><b>Heat directs to nasal mucosa.</b> <b>→reactivation old otitis media.</b></p> <p><b>→Valuated as first success in moving pathogen towards surface</b></p>



Klinik  
am Steigerwald

Chinesische Medizin und  
biologische Heilverfahren





# Therapy 19/01/21

<b>Findings, Anamnesis</b>	<b>therapeutical intention</b>	<b>Decotion</b>	<b>Result, interpretation</b>
<p>Consultation via Phone: Periode: day 3 Bowel movement good, sleep good</p> <p><b>Otitis media</b> Fatigue much better 4km walk possible</p>	<p>Open surface, expel wind- dampness</p> <p>push out heteropathia</p>	<p>Scutellaria R 2g Coicis S 6g Angelica dahurica 3g Magnolia Fl 2g Xanthii Fr. 2g</p> <p><b>Huangqin 2g</b> <b>Yiyiren 6g</b> <b>Baizhi 3g</b> <b>Xinyi 2g</b> <b>Cangerzi 2g</b></p>	<p>after 5 days Otitis good, only little nasal discharge.  (lasercoagulated situs)</p> <p><b>Fatigue better.</b></p>



# Proceeding

- We repeated this proceeding 3 times, almost every known inflammation focus reactivated
- We individually treated mucosal inflammation foci (otitis, sinusitis, bronchitis, cystitis, enteritis)
- Step by step reducing fatigue until today
- No more antibiotics were needed

Main difficulty:

Problems with reactivation of **lasercoagulated nasal mucosa**





# Conclusion of this case

- **CFS type 2:** with cold invasion in the past and a lot of reactive heat.
- We found some specific Post-Covid symptoms (**dyspnea, tachcardia, chest discomfort, anxiety**)
- These symptoms decreased by expelling dampness and cooling heat with **Scut-Kush** in the beginning of treatment process.
- **The healing progress could be reactivating physiological immune activity in the respiratory mucosa**



# General Conclusion

- At this moment we treat Post-Covid-Syndrome in the same way as other post-infectious chronic fatigue-syndromes
- 80% of our patients had immune disorders before Covid-infection.
- Most of the Patients showed symptoms as **dyspnea, palpitations, chest-discomfort, anxiety. About 20% had ageusia and anosmia in addition.**
- **We treated these symptoms by eliminating damp-heat and reducing stagnation. E.g. Scut-Kush, Coptis-kush or Coptis-Deca-Sieg.**
- **Chronic fatigue is getting better by raising immune activity from the inside to the mucosal level and promoting mucosal discharge.**